

Genetics of inherited platelet disorders

M. Gothwal; K. Sandrock-Lang; B. Zieger

Department of Paediatrics and Adolescent Medicine, University Medical Center Freiburg, Germany

Keywords

Platelets, inherited platelet disorders, molecular genetics, bleeding disorder

Summary

The current review describes inherited platelet disorders, illustrates their clinical phenotype and molecular genetic defects. Platelets are the key molecules mediating haemostasis via adhesion, activation and clot formation at the site of injury. The inherited platelet disorders can be classified according to their platelet defects: receptor/cytoskeleton defects, secretion disorder, and signal transduction defect.

Patients with inherited thrombocytopathia present with mucous membrane bleedings (epistaxis, gingival bleeding) and may present with serious life threatening bleedings following surgery or trauma. Therefore, biochemical and molecular genetic characterization of inherited platelet disorders is important to understand these disorders and to support an efficient therapy.

Schlüsselwörter

Thrombozyten, angeborene Thrombozytopathien, molekulare Genetik, Blutungsneigung

Zusammenfassung

Dieser Review beschreibt angeborene Thrombozytopathien, deren klinischen Phänotyp sowie die verursachenden molekulargenetischen Defekte. Thrombozyten sind die Schlüsselproteine, die mittels Adhäsion, Aktivierung und Thrombusbildung an der Verletzungsstelle zur Hämostase beitragen. Die angeborenen Thrombozytopathien werden entsprechend des Thrombozytendefekts eingeteilt: Rezeptor-/Zytoskelett-, Sekretions- oder Signaltransduktionsdefekt.

Patienten mit angeborener Thrombozytopathie leiden unter Schleimhautblutungen (Nasen- und Zahnfleischblutungen) und können sogar lebensbedrohliche Blutungen im Rahmen von Operationen und Unfällen entwickeln. Daher ist die biochemische und molekulargenetische Charakterisierung der angeborenen Thrombozytopathien wichtig zum Verständnis dieser Erkrankungen und zur Unterstützung einer effizienten Therapie.

Correspondence to:

Prof. Dr. Barbara Zieger
Department of Paediatrics and Adolescent Medicine
University Medical Center Freiburg
Mathildenstraße 1, 79106 Freiburg, Germany
E-mail: barbara.zieger@uniklinik-freiburg.de
Tel. +49/(0)761/27 04 30 00, Fax +49/(0)761/27 04 58 20

Genetik angeborener Thrombozytopathien

Hämostaseologie 2014; 34: 133–141
<http://dx.doi.org/10.5482/HAMO-13-09-0049>
received: September 6, 2013
accepted in revised form: December 11, 2013
prepublished online: December 19, 2013

This review will provide an overview of most of the inherited platelet disorders and their molecular genetics.

- Platelets are capable of binding several extracellular matrix proteins via their cell surface receptors and soluble ligands and thus propagate the prevention of blood loss, haemostasis and healing.

- Platelets are generated from polyploid megakaryocytes in the bone marrow.
- Their lifespan is approximately 7–10 days after which they are eliminated in the reticulo-endothelial system (1).

Several platelet surface glycoprotein (GP) complexes have been described. Platelets

consist of the intracellular organelles like mitochondria, Golgi, endoplasmic reticulum and ribosomes but are devoid of nucleus. They comprise three types of secretory granules:

- α -granules,
- δ -granules and
- lysosomes.

Blood vessel injury and an increased shear stress cause platelet activation. Activated platelets participate in adhesion, aggregation, shape change and secretion.

- After injury, the initial reaction is an attachment of platelet GPIb/IX/V complex to the von Willebrand factor (VWF) and to collagen.
- This binding initiates platelet adhesion to the subendothelial matrix and forms the basis for platelet activation.

Platelets are capable of direct interaction with collagen via their GPIa/IIa and GPVI complexes on their surface (2). Activation of platelets due to exposure to VWF, collagen and thrombin leads to conversion of GPIIb/IIIa complex (also called integrin α Ib β 3) into its active conformation and tight tethering to fibrinogen and VWF. Binding of the integrin α Ib β 3 to various soluble ligands (like fibrinogen, vitronectin, fibronectin and VWF) bridges the adjacent platelets and leads to formation of a platelet plug (3).

Inherited platelet disorders

Platelets play an important role in primary haemostasis. Patients with inherited platelet disorders present with

- mucous membrane bleedings (epistaxis, gingival bleeding) and
- may present with serious life threatening bleedings following surgery or trauma.
- Women mostly present with menorrhagia.

The inherited platelet disorders can be classified according to platelet defects:

- receptor/cytoskeleton defects (e.g. GPIb/IX/V or GPIIb/IIIa receptors),
- secretion defects (e.g. α - or δ -granule),
- signal transduction defects.

Membrane/cytoskeleton defects

Bernard-Soulier syndrome (BSS)

BSS was firstly described by Jean Bernard and Jean Pierre Soulier in 1948 (4). Its prevalence is 1:1 000 000.

- Patients with biallelic BSS (5) present with
 - severe bleeding tendency,
 - thrombocytopenia and
 - giant platelets.
- Heterozygous carriers present with
 - normal platelet counts and
 - normal platelet agglutination.

The biallelic form is autosomal recessively inherited. In BSS patients either the GPIb/IX/V complex is severely reduced or functionally impaired, causing a reduced binding of GPIba to VWF. The GPIb/IX/V complex (► Fig. 1a) is a product of the four genes *GP1BA*, *GP1BB*, *GP9* and *GP5*, located on chromosomes 17, 22, 3 and 3, respectively.

Platelet analysis in vitro reveals a severely impaired agglutination after stimulation with ristocetin.

Several homozygous mutations (>50) have been identified in *GP1BA*, *GP1BB* and *GP9* genes (6). Mutations within these genes led either to impaired trafficking of the complex through ER and Golgi apparatus or to synthesis of a truncated molecule (7, 8). Most BSS mutations have been found to be located in the *GP1BA* gene (7). Mutations in *GP5* do not contribute to BSS symptoms

Interestingly, one boy with deletion of *Sept5*, located 5' of *GP1BB*, presented with BSS, platelet secretion defect, cortical dysplasia and developmental retardation (9). Molecular genetic analysis revealed a homozygous 16.4 Kb deletion of two contiguous genes: *GP1BB* and *SEPT5*, present on chromosome 22 (► Fig. 1b). The recurrent life threatening bleeding episodes in this patient were successfully cured with stem cell transplantation.

The very rare monoallelic form of BSS shows autosomal dominant pattern of inheritance. The patients usually present with milder clinical symptoms, i.e. with mild or absent bleeding episodes (10). Most cases have been reported to carry the p.Ala156Val mutation in the *GP1BA* gene, resulting in a reduction of the GPIb/IX/V complex (11). Other mutations leading to monoallelic BSS include p.Leu57Phe, p.Tyr54Asp and p.Asn41His (12–14).

Platelet type VWD

The platelet type von-Willebrand disease (VWD), also known as pseudo VWD, was firstly described in 1982 (15) and follows an autosomal dominant inheritance pattern. The disease is characterized by spontaneous increased binding of platelet GPIba to VWF in circulation, thus leading to agglutination and eventually thrombocytopenia when these platelets are cleared from circulation.

- Patients present with mild to moderate mucocutaneous bleedings, especially following surgery.
- In addition, increased platelet agglutination with ristocetin at concentrations lower than that required for normal platelets is observed (16; 17).
- Although thrombocytopenia and bleeding is infrequent and mild, the symptoms tend to become severe under conditions such as pregnancy and infections (10; 17).

So far, four *GP1BA* gene mutations have been described, out of which three mutations (p.Gly233Val, p.Met238Val, p.Gly233Ser) are found within and one mutation (27 bp deletion) outside the VWF binding region (17).

Glanzmann thrombasthenia (GT)

GT was first described by Eduard Glanzmann in 1918 as a platelet abnormality presenting with haemorrhage and thrombasthenia (weak) platelets (18). Patients

- frequently present with recurrent bleeding such as epistaxis, mucocutaneous bleeding and hypermenorrhagia, and
- less commonly with gastrointestinal bleedings, intracranial haemorrhage and haematuria (8, 19).
- Interestingly, GT patients present a
 - prolonged bleeding time, but
 - normal platelet count and size.

An important diagnostic characteristic of GT platelets, in contrast to BSS platelets is

- normal agglutination after stimulation with ristocetin but
- impaired aggregation after stimulation with agonists like ADP, epinephrine, thrombin and collagen (20).

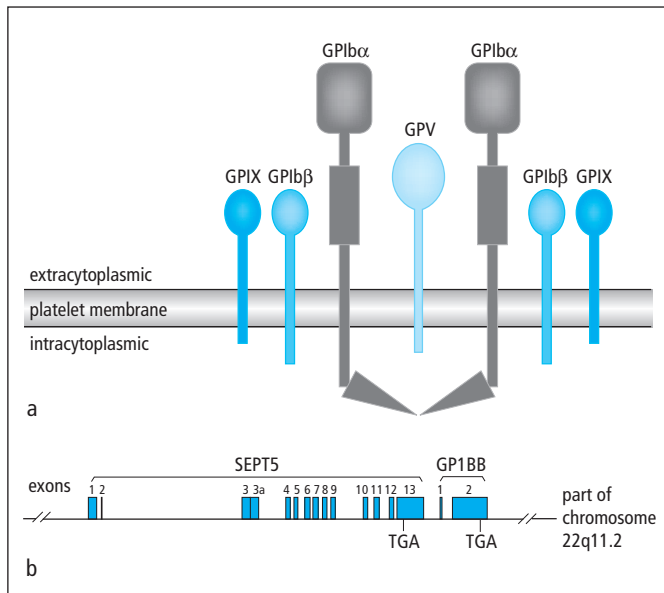


Fig. 1 Bernard-Soulier syndrome
 a) GPIb/IX/V receptor complex: Its deficiency or impaired function causes BSS.
 b) Location of SEPT5 and GP1BB genes on chromosome 22 (9)

Most patients with GT display an autosomal recessive mode of inheritance, caused by mutations in the genes *ITGA2B* and *ITGB3* which code for the integrin receptor subunits α Ib and β 3, respectively. Both human *ITGA2B* and *ITGB3* are located on chromosome 17.

GT is characterized by a reduced expression and/or an impaired function of α Ib β 3.

The integrin receptor α Ib β 3 (also known as GPIIb/IIIa complex) plays an important role in fibrinogen binding following platelet activation which is essential for subsequent platelet aggregation and formation of a platelet plug. Clot retraction, which is important for complete healing, is affected in GT patients and severely diminished in complete absence of GPIIb/IIIa (21).

Several *ITGA2B* and *ITGB3* gene mutations have been described leading to the autosomal recessive form of GT (21, 22). Most of the disease causing mutations are either homozygous or compound heterozygous and comprise of nonsense mutations, missense mutations, deletions and insertions. These mutations either

- affect the synthesis of receptor subunits in megakaryocytes or
- prevent the transport of pro-IIb/IIIa complex from ER to Golgi apparatus, wherein the normal pro-IIb/IIIa complex undergoes post-translational modifications and is finally transported to the cell surface (8, 21, 23).

As therapy tranexamic acid and platelet transfusion have been used successfully. In patients with GT and isoantibodies (anti HLA-alloimmunisation) activated FVII is recommended. In a few GT patients presenting with life threatening bleeding episodes and non-responsiveness to platelet transfusions hematopoietic stem cell transplantation (HSCT) has been performed successfully (19).

MYH9 associated platelet disorders

MYH9 related disease (MYH9-RD) encompasses the

- May-Hegglin anomaly,
- Fechtner syndrome,

- Epstein syndrome and
- Sebastian syndrome.

They follow an autosomal dominant inheritance pattern and are caused by mutations in the *MYH9* gene. *MYH9* is located on chromosome 22 and codes for non-muscle myosin, heavy chain (NMMHC-IIA), a cytoskeletal contractile protein. In MYH9-RD patients (24)

- the bleeding symptoms are often mild and they present with
- giant platelets,
- thrombocytopenia and may go on to
- develop sensori-neural hearing loss,
- presenile cataract and
- renal disorder.

Myosin 9 is composed of two heavy chains and two light chains. The heavy chain consists of an N-terminal motor domain, a neck region and a C-terminal tail domain (24).

- Mutations in the head region have been correlated to severe thrombocytopenia and high risk of early onset nephropathy and deafness.
- Mutations in the tail region have been observed to carry a milder phenotype with mild macrothrombocytopenia and a lower risk of additional complications (25).

Typically, in the blood smear of patients with MYH9-RD giant platelets and aggregates in leukocytes can be observed. Diagnosis of MYH9-RD is carried out by

- blood smear (with and without immunofluorescence microscopy),
- platelet electron microscopy and
- MYH9 gene sequencing.

Savoia et al. have recently shown myosin 9 immunofluorescence analysis in neutrophils of patients as a powerful tool for diagnosis of MYH9-RD (24). Myosin 9 immunofluorescence analysis on peripheral blood smears demonstrated a specific pattern of myosin 9 aggregates which correlated with the mutation. Patients with head domain mutations demonstrated numerous, small aggregates whereas patients with mutations in the tail domain displayed a few large, variously shaped aggregates.

Many cases of MYH9-RD are found to be caused due to de novo MYH9 gene mutations (24). There have been speculations on the exact mechanisms of thrombocytopenia caused by MYH9 mutations. Megakaryocytes (MKs) release platelets into the blood stream via extension of proplatelets. Collagen I prevents premature proplatelet formation in the osteoblastic niche until MKs have reached the blood vessel (26). ATPase activity of myosin IIA is important for proplatelet suppression, and in cases of MYH9 mutations this inhibitory effect is lost, leading to premature platelet release in the bone marrow (27). Pecci et al. studied proplatelet formation from MKs cultured from patients carrying the p.D1424N or the p.R1933X mutations (26). They found extension of proplatelets from MKs even upon adhesion to collagen I, indicating a loss of collagen I inhibition on proplatelet formation, thus supporting the hypothesis that MYH9 mutations could lead to a premature platelet release in bone marrow instead of in blood circulation causing thrombocytopenia (26).

Wiskott-Aldrich syndrome (WAS)

WAS, an X-linked recessively inherited syndrome (28), is characterized by

- microthrombocytopenia,
- immune deficiency,
- eczematoid dermatitis.

In addition, WAS patients (29) present with

- haemolytic anaemia,
- bloody diarrhea,
- arthritis,
- neutropenia and
- a poor prognosis.

WAS is caused by mutations in *WAS* gene located on the short arm of X chromosome and codes for the WASp protein.

In WASp deficient mice, ectopic proplatelet formation within the bone marrow was reported (30). WASp-deficient MKs showed defects in migration towards marrow sinusoids due to a lack of actin rich podosome structures essential for movement of MKs. Premature proplatelet formation and defective MK migration might be the mechanism leading to thrombocytopenia (30).

The WAS gene is also responsible for

- X-linked thrombocytopenia and
- X-linked neutropenia.

However, different mutations are involved. A recent report described occurrence of cytomegalovirus infection and thrombotic thrombocytopenic purpura (TTP) leading to diagnosis of WAS in a patient of Japanese origin (31). A novel deletion mutation in the WAS gene was identified in this patient (1345delG) leading to a truncated WAS protein.

Mutation in the WAS gene leading to TTP like disease is a novel finding (31).

So far, TTP has been described to be due to inhibition of the enzyme ADAMTS13 which is responsible for cleavage of VWF multimers (32). A failure in cleavage of VWF leads to increased platelet adhesion causing thromboses and damage to organs such as kidney, heart and brain.

Defect of collagen receptors

Patients with defects in the

- collagen receptors $\alpha 2\beta 1$ (GPIa/IIa) and GPVI display normal platelet count and morphology and present with mild bleeding episodes,
- platelet receptors $\alpha 2\beta 1$ or GPVI present with impaired platelet adhesion to collagen and reduced platelet activation by collagen, respectively (8).

Normal function of these receptors is important during the extension phase of platelet plug formation, which involves direct binding of platelet to collagen via these receptors (33). These disorders are caused by gene mutations in genes *ITGA2* (integrin $\alpha 2$, also known as GPIa) or *GP6* (glycoprotein 6) (8). *ITGA2* and *GP6* are located on chromosomes 5 and 19, respectively.

Defect of ADP receptor P2Y12

The autosomal recessively inherited defect in the P2Y12 (purinergic receptor P2Y, G-protein coupled, 12) receptors affects the

- extension and
- aggregation of platelets (33).

P2Y12 has been identified as an ADP receptor coded by the *P2Y12* gene present on chromosome 3. Genetic defects in the *P2Y12* gene lead to an impaired response of P2Y12 receptors to ADP. Most of the patients with *P2Y12* mutations display absent/diminished receptor expression or a defective ligand binding (8). In vitro studies demonstrate weak and unsustained platelet aggregation in response to ADP and normal aggregation in response to high concentrations of thrombin (33).

Secretion defects

Deficiency of or impaired secretion from α -granules, δ -granules or both comprises the secretion defects in platelets. Usually, platelet aggregation is affected indicating defects in the extension phase of clot formation.

Platelet α -granule secretion defects

Platelet α -granules contain various proteins like VWF, P-selectin, fibronectin, fibrinogen, coagulation factors like factors V and XIII and several growth factors like PDGF, TGF- β . Defective secretion of these proteins due to absence or decreased α -granules results in the following secretion defects.

Gray platelet syndrome (GPS)

GPS has been described as a platelet defect with selective absence/decrease of α -granules (34).

Typically, in the peripheral blood smear enlarged and gray coloured platelets are visible.

Patients present with

- thrombocytopenia,
- bleeding symptoms like epistaxis, petechiae, mucosal membrane bleeding and
- a prolonged bleeding time.

Many patients display an early onset of myelofibrosis and splenomegaly (8). Most cases have demonstrated an autosomal recessive pattern of inheritance. Platelet aggregation studies show a variable response pattern with different agonists.

In GPS patients, Maynard et al. reported the presence of 'ghost granules', indicating a defective incorporation of endogenously synthesized proteins such as P-selectin and Glut3 into α -granules (35).

Gunay-Aygun et al mapped the GPS genes to a 9.4 Mb region on chromosome 3p (36). More recently, exome sequencing in four unrelated GPS patients identified the gene *NBEAL2* (neurobeachin-like 2 gene) on chromosome 3 as the cause of GPS (37). Mutations in the *NBEAL2* gene have been described to be either homozygous or compound heterozygous (37–39). Silencing studies with zebrafish embryos resulted in complete block of platelet formation and spontaneous bleeding in the tail. Erythropoiesis was found to be normal, indicating an essential role of *NBEAL2* protein in thrombopoiesis and GPS (37).

Quebec platelet disorder (QPD)

QPD follows an autosomal dominant inheritance pattern and was named after the Quebec region in Canada where the first families were identified with this bleeding disorder. Patients display delayed-onset-bleeding (12–24 hours after haemostatic challenge) and have been described (40) with

- increased bruising,
- joint bleeds and
- spontaneous haematuria.
- Excessive bleeding and
- delayed wound healing have been also observed.

Platelet aggregometry shows an impaired response to epinephrine with or without reduced aggregation with ADP and collagen (41). α -granule ultrastructure is normal; however, degradation of α -granule contents is increased.

Mutations in the *PLAU* gene which codes for urokinase-type plasminogen activator (u-PA), a fibrinolytic serine protease, cause QPD. In QPD patients, increased u-PA mRNA is found during megakaryocyte differentiation. u-PA, which is stored in platelet α -granules, promotes via increased plasmin generation the degradation of the other α -granule proteins like P-selectin (42). Direct tandem 78 Kb duplication in the genome covering this gene

has been found in all family members with QPD (43).

QPD patients respond better to fibrinolytic inhibitors (tranexamic acid) than to platelet transfusions.

Platelet δ -granule secretion defects

Patients with platelet δ -granule defect alone or with combined platelet α - and δ -granule defect or with associated clinical symptoms have been described. Deficiency of δ -granule (storing ATP, ADP, serotonin, calcium) in platelets in addition to abnormal secretion from other lysosome related organelles (LROs) has been observed in

- Hermansky Pudlak syndrome and
- Chediak Higashi syndrome.

Hermansky Pudlak syndrome (HPS)

HPS has been recognized as a genetically heterogeneous set of related conditions characterized by defects in lysosomes and LROs. It has been described as a rare autosomal recessive disorder, wherein the patients present (44) with

- oculocutaneous albinism,
- congenital nystagmus,
- pigmented macrophages in bone marrow and lymph nodes and
- lifelong bleeding problems.

Mutations in the HPS genes 1–9 can cause the disease (HPS1–9) (41, 45–47). In some patients with HPS1 and HPS4, respectively, pulmonary fibrosis (48) and granulomatous colitis has been observed. Typically, patients with HPS2 suffer additionally from

- immunodeficiency and present with
- neutropenia and
- recurrent infections.

A single patient with HPS2 developed haemophagocytic lymphohistiocytosis (HLH) (49, 50). Typically, in HPS patients

- bleeding time is severely prolonged,
- peripheral blood smear normal.
- Platelet aggregometry reveals moderately to severely impaired aggregation,
- flow cytometry analysis reveals defective platelet δ -granule secretion.

CD63 expression on platelets after stimulation with thrombin is absent in HPS patients (51). Typically, in HPS2 patients CD63 expression is already elevated on resting platelets (indicating lysosomal mis-sorting) and does not increase further after thrombin stimulation (49, 52).

HPS protein complexes are present in the BLOC complexes (biogenesis of lysosome-related organelle complexes; BLOC1, BLOC2, BLOC3 and AP-3) which are important for membrane and protein trafficking along the endocytic/lysosomal pathway (41, 53). In humans, molecular defects in nine genes have been identified (*HPS1-HPS9*) (41, 46, 47).

Defects in proteins HPS1-HPS9 encoded by these genes affect the BLOCs and in turn the biogenesis and function of intracellular organelles found in LROs like platelets, melanocytes, T-cells, neutrophils (46, 54).

Recently, we reported on a HPS2 patient presenting with characteristic features of HPS2 who developed severe bleeding post tonsillectomy (52). The patient displayed a novel 2 bp-deletion (c.3222_3223delTG) in the last exon of *AP3B1* gene leading to an altered prolonged protein product.

The identification of HPS9 was first reported in a boy of Indian origin (47) presenting with

- oculocutaneous albinism,
- reduced retinal pigmentation,
- nystagmus and
- absence of platelet δ -granules.

Screening of the BLOC complexes revealed a homozygous nonsense mutation in the *PLDN* gene (which encodes for pallidin) present in the BLOC1. The mutation was identified as c.232C>T in exon 3 of *PLDN* gene present on chromosome 15, resulting in a protein mutation p.Q78X and a shortened 78 amino acids long pallidin protein. The transcript 1 coding for full length pallidin was present. However, western analysis showed a complete absence of pallidin in fibroblasts, indicating an unstable mutant protein (47). The expression of other BLOC1 subunits cappuccino and snapin was also affected indicating an essential role of pallidin in this complex.

Chediak-Higashi syndrome (CHS)

CHS is a rare autosomal recessive disease described by Chediak and Higashi in 1955 as a leukocyte anomaly and gigantism of peroxidase granules (55). Patients present with

- oculocutaneous albinism,
- immunodeficiency,
- bleeding tendency and
- progressive neurological disorder.
- Some patients develop HLH (56).

Most patients do not reach adulthood. Peripheral blood smear shows giant inclusion bodies in leukocytes. Diagnostic investigation (41, 45, 56) is usually performed with

- ophthalmologic examination (impaired iris pigmentation and transillumination),
- light microscopy of hair (pigment clumping in hair shafts),
- flow cytometry and electron microscopy (impaired platelet δ -granules secretion),
- NK cell cytotoxicity and platelet aggregation (impaired secondary wave of aggregation).

Patients with CHS display frameshift and nonsense mutations (severe phenotype) and missense mutations (milder phenotype) in *LYST* (lysosomal trafficking regulator) gene present on chromosome 1. *LYST*, the product of this gene is predicted to be a cytosolic protein, regulating trafficking and size of LROs. Most CHS patients succumb to life threatening bacterial infections due to severe immunodeficiency.

A recent report identified the presence of the same novel homozygous *LYST* mutation in both siblings of consanguineous parents but presenting with different clinical phenotypes (56). The mutation was identified as c.5506C>T leading to a premature stop codon. The elder girl was born with dark hair and skin whereas her brother with fair hair and skin. Post *Salmonella* infection, the girl developed first signs of CHS: abnormal pigmentation in hair shaft, presence of histiocytes in bone marrow and hypopigmented skin areas. The younger sibling (5 months) developed pancytopenia and hepatosplenomegaly post influenza A infection and died from active disease phase. Both

Tab. 1 Diagnosis of inherited platelet disorders

inherited platelet disorder	symptoms, history	blood examination	further tests, assays	ref.	
membrane and cytoskelet on defects	Bernard-Soulier syndrome	<ul style="list-style-type: none"> frequent bleeding episodes severe bleeding tendency mucocutaneous bleeding prolonged bleeding time 	<ul style="list-style-type: none"> thrombocytopenia giant platelets 	impaired platelet agglutination with ristocetin	5
	platelet-type VWD	mild to moderate mucocutaneous bleedings, esp. post surgery	thrombocytopenia	increased platelet agglutination with ristocetin	16, 17
	Glanzmann thrombasthenia	<ul style="list-style-type: none"> frequent bleeding episodes severe bleeding tendency mucocutaneous bleeding prolonged bleeding time 	normal platelet count and size	platelet aggregation/agglutination <ul style="list-style-type: none"> impaired with ADP, epinephrine, thrombin and collagen normal with ristocetin 	8, 19, 20
	MYH9-related disease	<ul style="list-style-type: none"> mild bleeding symptoms additional complications like sensori-neural hearing loss, renal disorder, presenile cataract 	<ul style="list-style-type: none"> thrombocytopenia giant platelets myosin 9 aggregates in leukocytes 	platelet aggregation normal	24
	Wiskott-Aldrich syndrome	<ul style="list-style-type: none"> immune deficiency eczematoid dermatitis bloody diarrhea arthritis 	<ul style="list-style-type: none"> microthrombocytopenia neutropenia haemolytic anemia 	decreased platelet aggregation	28, 29
	defect of collagen receptors $\alpha 2\beta 1$ and GP6	mild bleeding episodes	normal platelet count and morphology	<ul style="list-style-type: none"> $\alpha 2\beta 1$: impaired platelet adhesion to collagen GP6: impaired platelet activation by collagen 	8, 62
	defect of ADP receptor P2Y12			platelet aggregation <ul style="list-style-type: none"> weak and unsustainable with ADP normal with high thrombin concentrations 	33, 63

siblings presented with absence of NK cell cytotoxicity and reduced NK cell degranulation upon stimulation with NK sensitive target cells. In both patients, lytic granule exocytosis was affected, however, the severity and extent of disease phenotype was variable.

HSCT has been the choice of treatment for CHS patients.

Griscelli syndrome (GS)

GS is an autosomal recessive disorder characterized by normal platelet count but an absence of or abnormal δ -granules. Patients (8, 45, 57) present with

- albinism,
- neurological defects and
- lymphohistiocytosis,
- hair hypopigmentation and
- uneven distribution of pigment in hair shafts.

Three kinds of GS have been recognized: GS1, GS2 and GS3 (45). They are defined by different genetic defects and thus variable clinical manifestations.

GS1 is caused by mutations in the *MYO5A* gene present on chromosome 15, coding for actin associated myosin Va motor protein.

- Most GS1 patients display neurological abnormalities, however,
- those with mutations in the exon F on *MYO5A* present only with hypopigmentation (45).

GS2 is a manifestation of mutations in the *Rab27a* gene located on chromosome 15, which codes for the small GTPase Rab27a involved in protein transport and signal transduction. Typically, patients display

- oculocutaneous albinism,
- silver hair and
- recurrent infections (58).

Most patients do not present with neurological impairment, except secondary to leukocyte infiltration in the brain (45, 58). In a young boy with *Rab27a* heterozygous mutation, GS2 was suspected (49). The boy additionally presented with impaired NK and T-cell cytotoxicity. However, following a serious bleeding episode in combination with abnormal platelet aggregation, neutropenia, impaired CD63 expression (like in HPS2) and absence of platelet δ -granules, HPS2 was diagnosed. A novel homozygous mutation in *AP3B1* gene was found in this patient.

GS3 is caused by mutations in the *MLPH* gene present on chromosome 2, coding for melanophilin. The first mutation that led to the identification of GS3 was described to be a missense *MLPH* mutation c.102C>T, leading to p.R35W in the melanophilin protein (57). Recently, seven new GS3 cases of Arabic origin were reported to carry the same mutation (59).

Tab. 1 Diagnosis of inherited platelet disorders, continued

inherited platelet disorder	symptoms, history	blood examination	further tests, assays	ref.	
secretion defects	Gray platelet syndrome	<ul style="list-style-type: none"> prolonged bleeding time epistaxis, petechiae, mucosal membrane bleeding early onset of myelofibrosis and splenomegaly 	<ul style="list-style-type: none"> thrombocytopenia enlarged and gray platelets absent or reduced α-granules 	variable response pattern with different agonists	8, 34
	Quebec platelet disorder	<ul style="list-style-type: none"> delayed-onset-bleeding increased bruising joint bleeds spontaneous haematuria 	<ul style="list-style-type: none"> normal α-granule ultra-structure increased degradation of its contents 	impaired response to epinephrine	40, 41
	Hermansky-Pudlak syndrome	<ul style="list-style-type: none"> oculocutaneous albinism, congenital nystagmus, life-long bleeding problems HPS1 and HPS4: pulmonary fibrosis, granulomatous colitis HPS2: immunodeficiency, recurrent infections 	<ul style="list-style-type: none"> normal platelet count absent or few platelet dense bodies neutropenia in HPS2 	<ul style="list-style-type: none"> moderately to severely impaired aggregation absent CD63 expression after thrombin stimulation 	44, 48, 51
	Chediak-Higashi syndrome	<ul style="list-style-type: none"> oculocutaneous albinism immunodeficiency bleeding tendency progressive neurological disorder 	giant inclusion bodies in leukocytes	<ul style="list-style-type: none"> impaired platelet δ-granule secretion and platelet aggregation impaired iris pigmentation pigment clumping in hair shafts NK cell degranulation defect 	41, 45, 56
	Griscelli syndrome	<ul style="list-style-type: none"> albinism neurological defects lymphohistiocytosis hair hypopigmentation 	<ul style="list-style-type: none"> normal platelet count absence of δ-granules 	<ul style="list-style-type: none"> NK cell degranulation defect defective platelet aggregation in <i>ashen</i> mouse (murine counterpart of GS2) 	8, 45, 57, 64
	signal transduction defects	LADIII		impaired aggregation (Glanzmann-like)	60, 61
<ul style="list-style-type: none"> leukocytosis severe bleeding osteofibrosis immunodeficiency 					
	cyclooxygenase defect		impaired aggregation with collagen, ADP, epinephrine and arachidonic acid		

The three proteins myosin Va, Rab27a and melanophilin form a heterotrimeric protein complex which is essential for melanosome transport (57).

A defect in any of these proteins leads to impaired pigmentation. The R35W mutation in melanophilin inhibited its interaction with Rab27a and thus manifestation of GS3 clinical symptoms.

Signal transduction defects

A few patients with signal transduction defects have been described. These defects comprise of defects in

- cytosolic phospholipase A2a,

- cyclooxygenase (aspirin-like defect),
- thromboxane synthase,
- GTP-binding proteins,
- phospholipase C activation,
- transcription factors (e.g., mutation in *RUNX1* gene).

In patients with cyclooxygenase defect the initial steps of prostaglandin synthesis are affected. The defect manifests itself similar to aspirin consumption, wherein irreversible acetylation of platelet cyclooxygenase is observed.

- Platelet aggregation after stimulation with collagen, ADP, epinephrine and arachidonic acid is reduced, whereas

- aggregation after thromboxane A2 (TXA2) stimulation is normal.
- The platelet TXA2 production which activates the thromboxane receptor and supports platelet activation is missing.

The leukocyte adhesion deficiency III (LADIII) is also characterized by signaling defects. Patients present with

- leukocytosis,
- severe bleeding,
- frequent infections,
- Glanzmann-like platelet defect and
- sometimes osteofibrosis (60, 61).

LADIII is shown to result from mutations in *FERMT3* gene, which codes for Kind-

lin-3. An inability to activate integrins present on haematopoietic cells like platelets and leukocytes has been identified as the cause of LADIII. Presence of the impaired Kindlin-3 in patients resulted in defective activation of the integrin $\alpha\text{IIb}\beta\text{3}$ and thus decreased fibrinogen binding (60). Thus, Kindlin-3 has been identified to be essential for activation of integrin $\alpha\text{IIb}\beta\text{3}$ in humans. HSCT has been successfully used to treat the bleeding symptoms and immunodeficiency in LADIII patients (60, 61).

Conclusion

Correct and efficient diagnosis of inherited platelet disorders is essential for treatment and management of symptoms. Much progress has been made with respect to the array of methods employed for diagnosis.

Molecular genetic analysis is carried out for most of the disorders.

It plays an important role in diagnosis when symptoms and preliminary investigations are not sufficient to make a conclusion for therapy. An overview of diagnosis discussed in this review is provided (► Tab. 1). Understanding the clinical phenotype (patient history, peripheral blood, platelet characteristics) together with the molecular genetic defect helps in accurate diagnosis and supports therapy. Finally, all therapeutic procedures need to be carefully considered based on the individual patient characteristics and family history.

Conflict of interest

The authors declare that they do not have any conflict of interest.

References

- Frojmovic MM, Milton JG. Human platelet size, shape, and related functions in health and disease. *Physiol Rev* 1982; 62: 185–261.
- Santoro SA, Zutter MM. The alpha 2 beta 1 integrin: a collagen receptor on platelets and other cells. *Thromb Haemost* 1995; 74: 813–821.
- Bennett JS. Structure and function of the platelet integrin $\alpha\text{IIb}\beta\text{3}$. *J Clin Invest* 2005; 115: 3363–3369.
- Bernard J, Soulier J. Sur une nouvelle variété de dystrophie thrombocytaire-hémorragique congénitale. *Sem Hop* 1948; 24: 3217–3223.
- López JA, Andrews RK, Afshar-Kharghan V, Berndt MC. Bernard-Soulier syndrome. *Blood* 1998; 91: 4397–4418.
- Savoia A, Pastore A, De Rocco D et al. Clinical and genetic aspects of Bernard-Soulier syndrome: searching for genotype/phenotype correlations. *Haematologica* 2011; 96: 417–423.
- Salles II, Feys HB, Iserbyt BF et al. Inherited traits affecting platelet function. *Blood Rev* 2008; 22: 155–172.
- Nurden A, Nurden P. Advances in our understanding of the molecular basis of disorders of platelet function. *J Thromb Haemost* 2011; 9 (Suppl 1): 76–91.
- Bartsch I, Sandrock K, Lanza F et al. Deletion of human GP1BB and SEPT5 is associated with Bernard-Soulier syndrome, platelet secretion defect, polymicrogyria, and developmental delay. *Thromb Haemost* 2011; 106: 475–483.
- Balduini CL, Savoia A. Genetics of familial forms of thrombocytopenia. *Hum Genet* 2012; 131: 1821–1832.
- Savoia A, Balduini CL, Savino M et al. Autosomal dominant macrothrombocytopenia in Italy is most frequently a type of heterozygous Bernard-Soulier syndrome. *Blood* 2001; 97: 1330–1335.
- Miller JL, Lyle VA, Cunningham D. Mutation of leucine-57 to phenylalanine in a platelet glycoprotein Ib alpha leucine tandem repeat occurring in patients with an autosomal dominant variant of Bernard-Soulier disease. *Blood* 1992; 79: 439–446.
- Kunishima S, Imai T, Hamaguchi M, Saito H. Novel heterozygous missense mutation in the second leucine rich repeat of GPIbalpha affects GPIb/IX/V expression and results in macrothrombocytopenia in a patient initially misdiagnosed with idiopathic thrombocytopenic purpura. *Eur J Haematol* 2006; 76: 348–355.
- Vettore S, Scandellari R, Moro S et al. Novel point mutation in a leucine-rich repeat of the GPIbalpha chain of the platelet von Willebrand factor receptor, GPIb/IX/V, resulting in an inherited dominant form of Bernard-Soulier syndrome affecting two unrelated families: the N41H variant. *Haematologica* 2008; 93: 1743–1747.
- Weiss HJ, Meyer D, Rabinowitz R et al. Pseudo-von Willebrand's disease. An intrinsic platelet defect with aggregation by unmodified human factor VIII/von Willebrand factor and enhanced adsorption of its high-molecular-weight multimers. *N Engl J Med* 1982; 306: 326–333.
- Miller JL, Castella A. Platelet-type von Willebrand's disease: characterization of a new bleeding disorder. *Blood* 1982; 60: 790–794.
- Othman M. Platelet-type Von Willebrand disease: three decades in the life of a rare bleeding disorder. *Blood Rev* 2011; 25: 147–153.
- Glanzmann W. Hereditary haemorrhagic thrombasthenia. A contribution to the pathology of platelets. *Jahrbuch für Kinderheilkunde* 1918; 88: 1–42, 113–141.
- Wiegering V, Sauer K, Winkler B et al. Indication for allogeneic stem cell transplantation in Glanzmann's thrombasthenia. *Hamostaseologie* 2013; 33: 305–312.
- French DL, Seligsohn U. Platelet glycoprotein IIb/IIIa receptors and Glanzmann's thrombasthenia. *Arterioscler Thromb Vasc Biol* 2000; 20: 607–610.
- Kannan M, Saxena R. Glanzmann's thrombasthenia: an overview. *Clin Appl Thromb Hemost* 2009; 15: 152–165.
- Nurden AT. Glanzmann thrombasthenia. *Orphanet J Rare Dis* 2006; 1: 10.
- Lanza F. Bernard-Soulier syndrome (hemorrhagic platelet dysfunction). *Orphanet J Rare Dis* 2006; 1: 46.
- Savoia A, De Rocco D, Panza E et al. Heavy chain myosin 9-related disease (MYH9-RD): neutrophil inclusions of myosin-9 as a pathognomonic sign of the disorder. *Thromb Haemost* 2010; 103: 826–832.
- Pecci A, Panza E, Pujol-Moix N et al. Position of nonmuscle myosin heavy chain IIA (NMMHC-IIA) mutations predicts the natural history of MYH9-related disease. *Hum Mutat* 2008; 29: 409–417.
- Pecci A, Malara A, Badalucco S et al. Megakaryocytes of patients with MYH9-related thrombocytopenia present an altered proplatelet formation. *Thromb Haemost* 2009; 102: 90–96.
- Balduini A, Pallotta I, Malara A et al. Adhesive receptors, extracellular proteins and myosin IIA orchestrate proplatelet formation by human megakaryocytes. *J Thromb Haemost* 2008; 6: 1900–1907.
- Aldrich RA, Steinberg AG, Campbell DC. Pedigree demonstrating a sex-linked recessive condition characterized by draining ears, eczematoid dermatitis and bloody diarrhea. *Pediatrics* 1954; 13: 133–139.
- Bosticardo M, Marangoni F, Aiuti A et al. Recent advances in understanding the pathophysiology of Wiskott-Aldrich syndrome. *Blood* 2009; 113: 6288–6295.
- Sabri S, Foudi A, Boukour S et al. Deficiency in the Wiskott-Aldrich protein induces premature proplatelet formation and platelet production in the bone marrow compartment. *Blood* 2006; 108: 134–140.
- Kawasaki Y, Toyoda H, Otsuki S et al. A novel Wiskott-Aldrich syndrome protein mutation in an infant with thrombotic thrombocytopenic purpura. *Eur J Haematol* 2013; 90: 164–168.
- Sadler JE. Von Willebrand factor, ADAMTS13, and thrombotic thrombocytopenic purpura. *Blood* 2008; 112: 11–18.
- Simon D, Kunicki T, Nugent D. Platelet function defects. *Haemophilia* 2008; 14: 1240–1249.
- Raccuglia G. Gray platelet syndrome. A variety of qualitative platelet disorder. *Am J Med* 1971; 51: 818–828.
- Maynard DM, Heijnen HF, Gahl WA, Gunay-Aygun M. The α -granule proteome: novel proteins in normal and ghost granules in gray platelet syndrome. *J Thromb Haemost* 2010; 8: 1786–1796.
- Gunay-Aygun M, Zivony-Elboun Y, Gumruk F et al. Gray platelet syndrome: natural history of a large patient cohort and locus assignment to chromosome 3p. *Blood* 2010; 116: 4990–5001.
- Albers CA, Cvejic A, Favier R et al. Exome sequencing identifies NBEAL2 as the causative gene for gray platelet syndrome. *Nat Genet* 2011; 43: 735–737.
- Gunay-Aygun M, Falik-Zaccari TC, Vilboux T et al. NBEAL2 is mutated in gray platelet syndrome and

- is required for biogenesis of platelet α -granules. *Nat Genet* 2011; 43: 732–734.
39. Kahr WH, Hinckley J, Li L, Schwertz H et al. Mutations in NBEAL2, encoding a BEACH protein, cause gray platelet syndrome. *Nat Genet* 2011; 43: 738–740.
 40. McKay H, Derome F, Haq MA et al. Bleeding risks associated with inheritance of the Quebec platelet disorder. *Blood* 2004; 104: 159–165.
 41. Sandrock K, Zieger B. Current Strategies in diagnosis of inherited storage pool defects. *Transfus Med Hemother* 2010; 37: 248–258.
 42. Veljkovic DK, Rivard GE, Diamandis M et al. Increased expression of urokinase plasminogen activator in Quebec platelet disorder is linked to megakaryocyte differentiation. *Blood* 2009; 113: 1535–1542.
 43. Paterson AD, Rommens JM, Bharaj B et al. Persons with Quebec platelet disorder have a tandem duplication of PLAU, the urokinase plasminogen activator gene. *Blood* 2010; 115: 1264–1266.
 44. Hermansky F, Pudlak P. Albinism associated with hemorrhagic diathesis and unusual pigmented reticular cells in the bone marrow: report of two cases with histochemical studies. *Blood* 1959; 14: 162–169.
 45. Huizing M, Helip-Wooley A, Westbroek W et al. Disorders of lysosome-related organelle biogenesis: clinical and molecular genetics. *Annu Rev Genomics Hum Genet* 2008; 9: 359–386.
 46. Wei ML. Hermansky-Pudlak syndrome: a disease of protein trafficking and organelle function. *Pigment Cell Res* 2006; 19: 19–42.
 47. Cullinane AR, Curry JA, Carmona-Rivera C et al. A BLOC-1 mutation screen reveals that PLDN is mutated in Hermansky-Pudlak Syndrome type 9. *Am J Hum* 2011; *Genet* 88: 778–787.
 48. O'Brien K, Troendle J, Gochuico BR et al. Pirfenidone for the treatment of Hermansky-Pudlak syndrome pulmonary fibrosis. *Mol Genet Metab* 2011; 103: 128–134.
 49. Enders A, Zieger B, Schwarz K et al. Lethal hemophagocytic lymphohistiocytosis in Hermansky-Pudlak syndrome type II. *Blood* 2006; 108: 81–87.
 50. Jessen B, Bode SF, Ammann S et al. The risk of hemophagocytic lymphohistiocytosis in Hermansky-Pudlak syndrome type 2. *Blood* 2013; 121: 2943–2951.
 51. Sandrock K, Bartsch I, Rombach N et al. Compound heterozygous mutations in 2 siblings with Hermansky-Pudlak syndrome type 1 (HPS1). *Klin Padiatr* 2010; 222: 168–174.
 52. Kurnik K, Bartsch I, Maul-Pavicic A et al. Novel mutation in Hermansky-Pudlak syndrome type 2 with mild immunological phenotype. *Platelets* 2013; 24: 538–543.
 53. Huizing M, Parkes JM, Helip-Wooley A et al. Platelet alpha granules in BLOC-2 and BLOC-3 subtypes of Hermansky-Pudlak syndrome. *Platelets* 2007; 18: 150–157.
 54. Cutler DF. Introduction: lysosome-related organelles. *Semin Cell Dev Biol* 2002; 13: 261–262.
 55. Sato A. Chédiak and Higashi's disease: probable identity of a new leucocytal anomaly (Chédiak) and congenital gigantism of peroxidase granules (Higashi). *Tohoku J Exp Med* 1955; 61: 201–210.
 56. Kaya Z, Ehl S, Albayrak M et al. A novel single point mutation of the LYST gene in two siblings with different phenotypic features of Chediak Higashi syndrome. *Pediatr Blood Cancer* 2011; 56: 1136–1139.
 57. Ménasché G, Ho CH, Sanal O et al. Griscelli syndrome restricted to hypopigmentation results from a melanophilin defect (GS3) or a MYO5A F-exon deletion (GS1). *J Clin Invest* 2003; 112: 450–456.
 58. Jennane S, El Kababri M, Hessissen L et al. A hemophagocytic syndrome revealing a Griscelli syndrome type 2. *Ann Biol Clin (Paris)* 2013; 71: 461–464.
 59. Westbroek W, Klar A, Cullinane AR et al. Cellular and clinical report of new Griscelli syndrome type III cases. *Pigment Cell Melanoma Res* 2012; 25: 47–56.
 60. Jurk K, Schulz AS, Kehrel BE et al. Novel integrin-dependent platelet malfunction in siblings with leukocyte adhesion deficiency-III (LAD-III) caused by a point mutation in FERMT3. *Thromb Haemost* 2010; 103: 1053–1064.
 61. Malinin NL, Zhang L, Choi J et al. A point mutation in KINDLIN3 ablates activation of three integrin subfamilies in humans. *Nat Med* 2009; 15: 313–318.
 62. Dumont B, Lasne D, Rothschild C et al. Absence of collagen-induced platelet activation caused by compound heterozygous GPVI mutations. *Blood* 2009; 114: 1900–1903.
 63. D'Andrea G, Chetta M, Margaglione M. Inherited platelet disorders: thrombocytopenias and thrombocytopathies. *Blood Transfus* 2009; 7: 278–292.
 64. Novak EK, Gautam R, Reddington M et al. The regulation of platelet-dense granules by Rab27a in the ashken mouse, a model of Hermansky-Pudlak and Griscelli syndromes, is granule-specific and dependent on genetic background. *Blood* 2002; 100: 128–135.

